



# The dynamics of deglutition during head rotation using dynamic 320-row area detector computed tomography

Kazutaka Kochi MD<sup>1</sup> | Hirofumi Sei MD, PhD<sup>2,3</sup>  | Yuki Tanabe MD, PhD<sup>4</sup> |  
Kazunori Yasuda PhD<sup>5</sup> | Teruhito Kido MD, PhD<sup>4</sup> | Hiroyuki Yamada MD, PhD<sup>1</sup>  |  
Aki Taguchi MD, PhD<sup>6</sup> | Naohito Hato MD, PhD<sup>1</sup>

<sup>1</sup>Department of Otolaryngology, Head and Neck Surgery, Ehime University School of Medicine, Toon City, Japan

<sup>2</sup>Department of Otolaryngology, Head and Neck Surgery, Ehime Prefectural Central Hospital, Matsuyama, Ehime, Japan

<sup>3</sup>Department of Mechanical Systems Engineering, Graduate School of Science and Engineering, Yamagata University, Yonezawa City, Japan

<sup>4</sup>Department of Radiology, Ehime University Graduate School of Medicine, Toon City, Japan

<sup>5</sup>Department of Mechanical Engineering, Graduate School of Science and Engineering, Ehime University, Matsuyama City, Japan

<sup>6</sup>Faculty of Health and Welfare, Prefectural University of Hiroshima, Mihara, Japan

## Correspondence

Hirofumi Sei, Department of Otolaryngology, Head and Neck Surgery, Ehime Prefectural Central Hospital, 83 Kasuga Town, Matsuyama, Ehime 790-0024, Japan.  
Email: [hirofumisei@gmail.com](mailto:hirofumisei@gmail.com)

## Funding information

JSPS KAKENHI, Grant/Award Number: 22K17608

## Abstract

**Objective:** We aimed to elucidate the dynamics of deglutition during head rotation by acquiring 320-row area detector computed tomography (320-ADCT) images and analyzing deglutition during head rotation.

**Methods:** This study included 11 patients experiencing globus pharyngeus. A 320-ADCT was used to acquire images in two types of viscosity (thin and thick), with the head rotated to the left. We measured the movement time of deglutition-related organs (soft palate, epiglottis, upper esophageal sphincter [UES], and true vocal cords) and pharyngeal volume (bolus ratio at the start of UES opening [Bolus ratio], pharyngeal volume contraction ratio [PVCR], and pharyngeal volume before swallowing [PVBS]). A two-way analysis of variance was performed for statistical analysis, and all items were compared for significant differences in terms of head rotation and viscosity. EZR was used for all statistical analyses ( $p$ -value  $<.05$ ).

**Results:** Head rotation significantly accelerated the onset of epiglottis inversion and UES opening compared with no head rotation. The duration of epiglottis inversion with the thin viscosity fluid was significantly longer. The bolus ratio increased significantly with thick viscosity. There was no significant difference in viscosity and head rotation in terms of PVCR. PVBS increased significantly with head rotation.

**Conclusion:** The significantly earlier start of epiglottis inversion and UES opening due to head rotation could be caused by: (1) swallowing center; (2) pharyngeal volume; and (3) pharyngeal contraction force. Thus, we plan to further analyze swallowing with head rotation by combining swallowing CT with manometry and examine its relationship with pharyngeal contraction force.

**Level of Evidence:** 3b

## KEYWORDS

aspiration, computed tomography, deglutition, head rotation, pharynx

This is an open access article under the terms of the [Creative Commons Attribution-NonCommercial-NoDerivs](https://creativecommons.org/licenses/by-nc-nd/4.0/) License, which permits use and distribution in any medium, provided the original work is properly cited, the use is non-commercial and no modifications or adaptations are made.

© 2023 The Authors. *Laryngoscope Investigative Otolaryngology* published by Wiley Periodicals LLC on behalf of The Triological Society.

## 1 | INTRODUCTION

Pneumonia caused by dysphagia is a major cause of death in a super-aging society, with aspiration pneumonia ranking as the sixth leading cause of death in Japan in 2020.<sup>1</sup> Furthermore, dysphagia among older adults has evolved into a major medical and social problem, such as the increase in medical costs related to the treatment of dysphagia including aspiration pneumonia.<sup>2,3</sup>

Videofluorographic swallowing study (VFSS),<sup>4</sup> videoendoscopic examination of swallowing (VE),<sup>4</sup> electromyogram,<sup>5</sup> manometry,<sup>6</sup> and swallowing computed tomography (CT)<sup>7</sup> are some of the tests used to pathologically diagnose dysphagia. Among these tests, VFSS and VE are the most commonly performed. VFSS has a high temporal resolution, which allows for coronal and sagittal observation; however, its advantages are limited as the evaluation can only be performed in two dimensions and radiation exposure. Conversely, VE is simple, easy to reproduce, and capable of evaluating the pharyngolaryngeal sensation. However, it has difficulty in evaluating the amount of aspiration and esophageal disorders and can only perform two-dimensional evaluations. Therefore, we decided to focus on swallowing CT as a method of evaluation. Swallowing CT uses a dynamic 320-row area detector CT (320-ADCT), allowing a four-dimensional analysis of the mechanism of deglutition dynamics.

It is necessary to accurately comprehend the pathology of dysphagia through multiple tests that examine swallowing function and select rehabilitation and treatment appropriately.<sup>8</sup> There have been reports on the effectiveness of head-raising training investigated in a randomized controlled trial<sup>9</sup> and on the effectiveness of training of deglutition posture (neck flexion, neck rotation, recumbent position) and voluntary deglutition (effortful swallowing, Mendelsohn method, supraglottic swallowing, and super strong breath-holding swallowing) through a systematic review.<sup>10</sup> Thus, training methods should be consolidated and training effects should be evaluated to further build evidence for dysphagia treatment.

Head rotation is a method of postural adjustment aiming to reduce pharyngeal retention and improve passage through the esophagus by changing the shape of the pharynx and the flow path of the bolus by rotating the neck to one side (left or right).<sup>11</sup> It is frequently used clinically as a compensatory approach. However, the dynamics of deglutition during head rotation remain to be fully clarified. We aimed to understand the dynamics of deglutition during head rotation, which is a part of rehabilitation, by taking swallowing CT images and analyzing deglutition during head rotation.

## 2 | MATERIALS AND METHODS

### 2.1 | Study design

The study included 11 patients (six male and five female, average  $\pm$  standard deviation [SD]: 37.45  $\pm$  7 years) with globus pharyngeus and without organic abnormalities who requested to undergo a detailed examination with a 320-ADCT (Aquilion ONE; Canon Medical

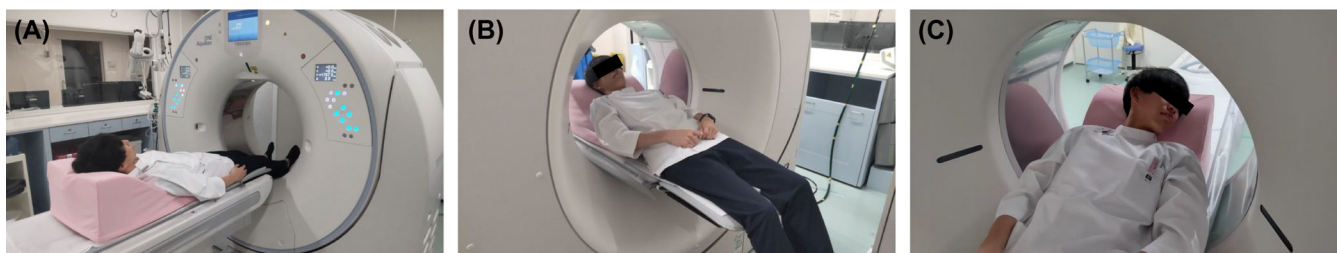Systems Corporation, Otawara, Japan). They had no gastroesophageal reflux disease in their medical history and no other diseases of note. Among the cases in which aspiration was observed with 10 mL of water in swallowing endoscopy, we excluded those with unstable respiratory conditions (i.e., the need for oxygen administration and frequent aspiration), cases already undergoing treatment for dysphagia, and cases who refused the use of their data. This study was conducted at Ehime university hospital between December 2020 and August 2021. All participants gave written informed consent to participate after receiving a full explanation of the objectives, study procedures, and risks of radiation exposure. The protocol for this study was approved by Ehime university hospital Institutional Ethics Review Board (approval number: 1906013).

We used a dynamic 320-row area detector CT system for performing a swallowing CT. The participants were immobilized in a semi-Fowler position at a reclining angle of 30°. We used a 10% diluted contrast medium (ioversol, iodine 320 mg/mL; Guerbet Japan, Tokyo, Japan) to prepare test liquids of two different viscosities. We adjusted the viscosity using a 10 mL thick liquid contrast medium (1550 mPa s, Honey), 10 mL thin liquid contrast medium (110 mPa s, Nectar), and a thickener (Tsurrinko Quickly, Clinico, Meguro-ku, Tokyo, Japan). Four patterns of CT imaging were performed using two types of viscosities with the head not rotated and rotated to the left (60°; Figure 1). The order of contrast agent and head rotation positions were randomly selected for each participant. Each participant was instructed to hold the contrast medium in their mouth until the CT operator instructed them to swallow. Imaging was started at the same time as the start of swallowing. The scan parameters were as follows: tube voltage/current, 120 kV/40 mA; scan time, 3.3 s; field of view, 320 mm; and scan range, 160 mm from the base of the skull to the upper esophagus. CT images were reconstructed through a 31-phase semi-reconstruction method with 0.1-s intervals (10 images/s) using a reconstruction technique (forward projection model-based iterative reconstruction solutions: FIRST, Body, standard). For a single swallowing CT scan, the volumetric CT dose index and dose-length product were estimated to be 7.4 mGy and 118.9 mGy cm.

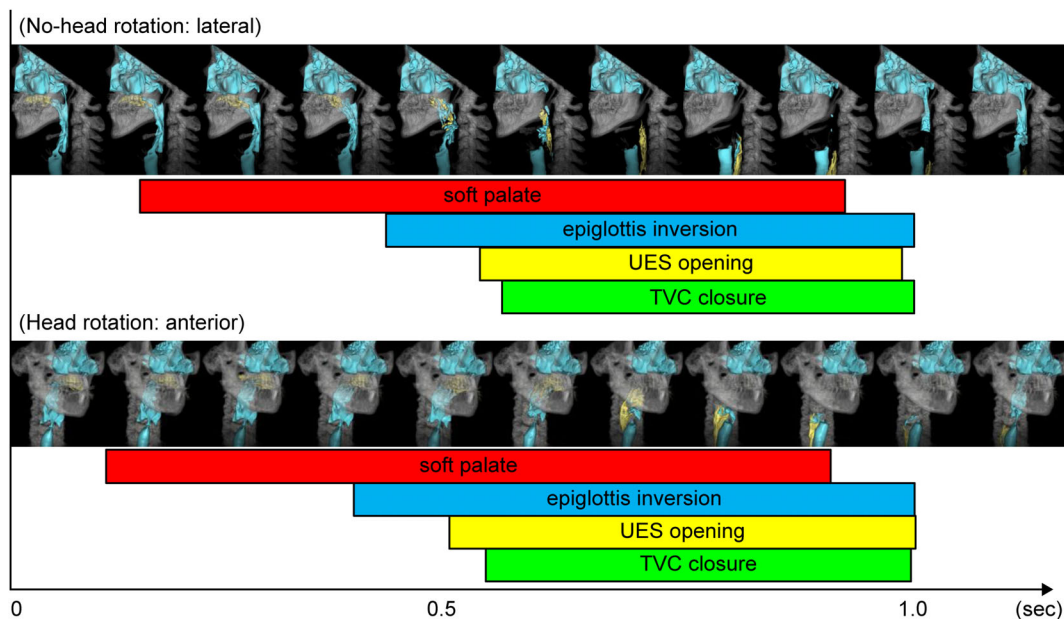
Each multi-planar reconstruction (MPR) image of swallowing (0.1-s interval per image) was used for the measurement. We measured the timing of deglutition-related organ events (soft palate elevation, epiglottis inversion, TVC, UES opening; Figure 2) and pharyngeal volume (pharyngeal cavity air and bolus volume at UES opening, pharyngeal volume contraction rate, pharyngeal volume before swallowing). All measurements were performed for each frame.

### 2.2 | Timing of swallowing-related organs

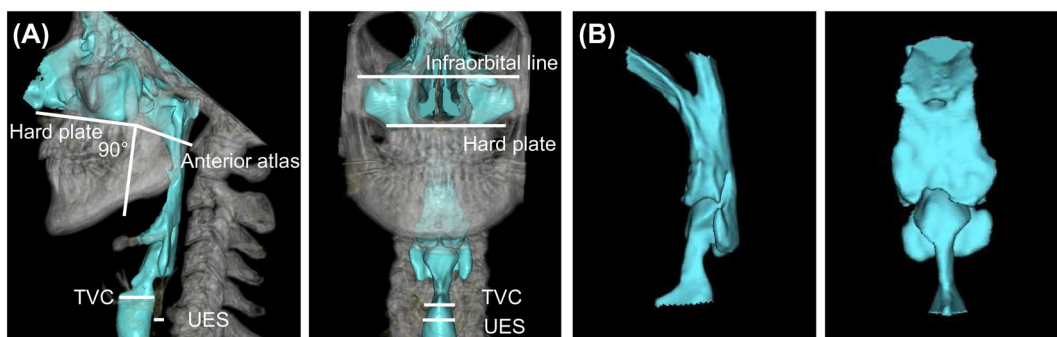
We measured the operation time of the soft palate, epiglottis, TVC, and UES as well as the onset time and duration of each organ. The soft palate was measured at initiation and termination of nasopharyngeal closure due to soft palate elevation. The epiglottis was measured at the onset and end of maximal epiglottic inversion. TVC was



**FIGURE 1** Imaging status of swallowing CT. (A) The participants are immobilized in a semi-Fowler position at a reclining angle of 30°. (B) Proceed to the CT scan position and fix it at the scan location (support the legs with a footstool). (C) Left head rotation is performed and CT imaging of the head rotation is acquired. CT, computed tomography.



**FIGURE 2** Computed tomography images of with and without head rotation and the timing of the swallowing-related organs. UES, upper esophageal sphincter; TVC, true vocal cords.

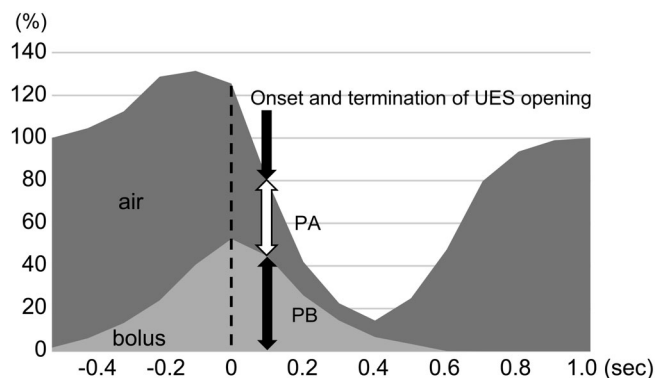


**FIGURE 3** Pharynx volume range. (A) Pharyngeal Volume Boundary Criteria (lateral, anterior) (lateral, anterior). (B) Pharynx volume only (lateral, anterior).

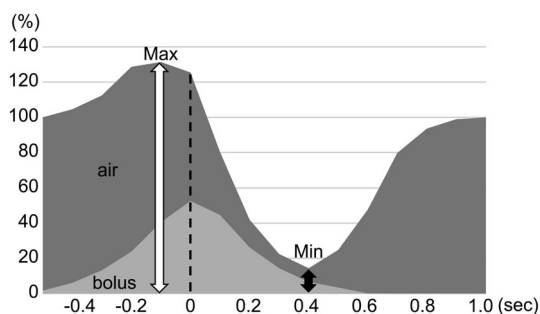
measured from the initiation to the termination of TVC closure. The opening and closing of the UES were measured. The baseline time of measurement (time 0) was defined as the onset of rapid upward movement of the hyoid bone.

### 2.3 | Pharyngeal volume

The pharyngeal cavity air and bolus volumes were measured in every frame using 3D rendered images. As for the scope of the pharyngeal



**FIGURE 4** Bolus ratio at the start of upper esophageal sphincter opening (Bolus ratio). The dotted line represents the onset of rapid superior movement of the hyoid bone. PA, percentage of air; PB, percentage of bolus.



**FIGURE 5** The pharyngeal volume contraction ratio. The dotted line represents the onset of rapid superior movement of the hyoid bone. The ratio is calculated as  $(MAX - MIN) / MAX \times 100$ .

volume, the superior surface includes the axial plane parallel to the suborbital line and passing through the posterior nasal spine (PNS) and from the PNS to the anterior end of the atlas; the anterior surface is the coronal plane through the PNS. Furthermore, the inferior surface includes the upper surface of the vocal cords and the axial surface of the upper UES (Figure 3). We calculated the bolus ratio of pharyngeal volume during UES opening. The air and bolus volumes were measured at each frame. The bolus volume was compared relative to the total pharyngeal volume at the start of UES opening as 100% (Figure 4). The maximum total volume (MAX) and minimum total volume (MIN) before swallowing were measured to determine the pharyngeal volume contraction ratio (PVCR), which was calculated as  $(MAX - MIN) / MAX$  (Figure 5). The pharyngeal volume before swallowing (PVBS) was compared. The pharyngeal volume was measured 0.5 s before the hyoid bone moved during swallowing. As there are individual differences in the volume of the pharynx, we calculated the relative volume of the thick viscosity fluid when the head was not rotated, the volume of thin and thick viscosity fluids when the head was rotated, and the thin viscosity fluid when the head was not rotated as the standard of 100%.

## 2.4 | Statistical analysis

Statistical analysis was performed using a two-way analysis of variance, the timing of deglutition-related organ events (soft palate elevation, epiglottis inversion, vocal cord closure, UES opening) between the tests, pharyngeal cavity and bolus volume, and PVCR. The pre-swallow pharyngeal volume was compared to identify any significant differences between viscosities and head rotation.  $p$ -Value  $< .05$  was considered statistically significant. EZR was used for all statistical analyses.<sup>12</sup>

## 3 | RESULTS

A 320-ADCT was performed for pharyngolaryngeal paresthesia, and no obvious organic abnormalities were observed in any of the participants in this study. All participants completed the swallowing CT, and no participants were excluded. The total effective dose in this study was 2.8 mSv ( $0.7 \text{ mSv} \times 4$  swallows).

### 3.1 | Timing of the deglutition-related organs

Table 1 shows the onset time of each deglutition-related organ. No significant differences were observed between the viscosities at any site.

In the case of the thin viscosity fluid, the time of onset of soft palate elevation was at  $-0.05 \pm 0.14$  s when the head was not rotated and  $-0.12 \pm 0.14$  s when the head was rotated. In the case of the thick viscosity fluid, it was at  $-0.10 \pm 0.18$  s when the head was not rotated and  $-0.14 \pm 0.12$  s when the head was rotated. No significant difference was observed in the time of onset of soft palate elevation with or without head rotation.

The time of onset of epiglottis inversion was significantly earlier when the head was rotated compared with that when the head was not rotated ( $0.11 \pm 0.07$  s and  $0.05 \pm 0.08$  s) for the thin and thick viscosity fluids ( $0.15 \pm 0.08$  and  $0.06 \pm 0.07$  s).

The time of onset of UES opening was significantly shortened from  $0.15 \pm 0.08$  s to  $0.07 \pm 0.09$  s for the thin viscosity fluid and from  $0.18 \pm 0.11$  to  $0.11 \pm 0.08$  s for the thick viscosity fluid.

The time of onset of TVC closure was  $0.15 \pm 0.11$  s when the head was not rotated and  $0.12 \pm 0.08$  s when the head was rotated for the thin viscosity fluid, whereas it was  $0.19 \pm 0.10$  s when the head was not rotated and  $0.12 \pm 0.10$  s when the head was rotated for the thick viscosity fluid. No significant differences were observed between the presence and absence of head rotation in terms of the time of onset of TVC closure.

Table 2 shows the duration of each swallowing-related organ event. No significant difference was observed between the presence and absence of head rotation at all sites.

The duration of soft palate elevation was  $0.62 \pm 0.20$  s for the thin viscosity fluid and  $0.64 \pm 0.17$  s for the thick viscosity fluid when

**TABLE 1** The onset time of each deglutition-related organ.

Onset time (s)	Thin		Thick		Thin head rotation		Thick head rotation		Head rotation p Value	Viscosity	Interaction
	Mean	SD	Mean	SD	Mean	SD	Mean	SD			
Soft palate	-0.05	0.14	-0.10	0.18	-0.12	0.14	-0.14	0.12	0.2321	0.4233	0.6880
Epiglottis inversion	0.11	0.07	0.15	0.08	0.05	0.08	0.06	0.07	0.0016	0.1709	0.5535
UES opening	0.15	0.08	0.18	0.11	0.07	0.09	0.11	0.08	0.0118	0.1948	1.0000
TVC closure	0.15	0.11	0.19	0.10	0.12	0.08	0.12	0.10	0.0741	0.5444	0.5444

Abbreviations: SD, standard deviation; TVC, true vocal cords; UES, upper esophageal sphincter.

**TABLE 2** The duration of each swallowing-related organ.

Duration (s)	Thin		Thick		Thin head rotation		Thick head rotation		Head rotation p Value	Viscosity	Interaction
	Mean	SD	Mean	SD	Mean	SD	Mean	SD			
Soft palate	0.62	0.20	0.64	0.17	0.63	0.16	0.59	0.12	0.7171	0.8562	0.5872
Epiglottis inversion	0.59	0.12	0.48	0.15	0.57	0.10	0.50	0.11	1	0.0171	0.6214
UES opening	0.40	0.08	0.37	0.09	0.44	0.11	0.45	0.11	0.076	0.763	0.5472
TVC closure	0.51	0.16	0.44	0.08	0.47	0.06	0.42	0.14	0.4461	0.0801	0.7989

Abbreviations: SD, standard deviation; TVC, true vocal cords; UES, upper esophageal sphincter.

**TABLE 3** The results of Bolus ratio, PVCR and PVBS.

(%)	Thin		Thick		Thin head rotation		Thick head rotation		Head rotation p Value	Viscosity	Interaction
	Mean	SD	Mean	SD	Mean	SD	Mean	SD			
Bolus ratio	52.59	12.84	76.51	9.93	58.93	16.22	72.42	8.79	0.7623	0.00001	0.1673
PVCR	94.76	4.93	93.83	4.62	94.95	3.79	91.59	6.91	0.5184	0.1779	0.4423
PVBS	100	-	114.15	35.82	134.58	57.10	137.60	61.55	0.0413	0.5363	0.6883

Abbreviations: Bolus ratio: bolus ratio at the start of upper esophageal sphincter opening; PVBS, pharyngeal volume before swallowing; PVCR, pharyngeal volume contraction ratio; SD, standard deviation.

the head was not rotated. When the head was rotated, the duration was  $0.63 \pm 0.16$  s for the thin viscosity fluid and  $0.59 \pm 0.12$  s for the thick viscosity fluid. No significant differences were observed between the viscosities in terms of the duration of soft palate elevation.

The duration of epiglottis inversion was  $0.59 \pm 0.12$  s for the thin viscosity fluid and  $0.48 \pm 0.15$  s for the thick viscosity fluid when the head was not rotated. The duration was  $0.57 \pm 0.10$  s for the thin viscosity fluid and  $0.50 \pm 0.11$  s for the thick viscosity fluid when the head was rotated. The duration of epiglottis inversion was significantly longer for the low viscosity fluid.

The duration of UES opening was  $0.40 \pm 0.08$  s for the thin viscosity fluid and  $0.37 \pm 0.09$  s for the thick viscosity fluid when the head was not rotated. The duration was  $0.44 \pm 0.11$  s for the thin viscosity fluid and  $0.45 \pm 0.11$  s for the thick viscosity fluid when the head was rotated. No significant differences were observed between the viscosities in terms of the duration of UES opening.

The duration of the vocal cord closure was  $0.51 \pm 0.16$  s for the thin viscosity fluid and  $0.44 \pm 0.08$  s for the thick viscosity fluid when the head was not rotated. The duration was  $0.47 \pm 0.06$  s for the thin viscosity fluid and  $0.42 \pm 0.14$  s for the thick viscosity fluid when the

head was rotated. No significant differences were observed between the viscosities in terms of the duration of TVC.

### 3.2 | Pharyngeal volume

Table 3 shows the results of the Bolus ratio, PVCR, and PVBS.

The bolus ratio was  $52.59 \pm 12.84\%$  for the thin viscosity fluid and  $76.51\% \pm 9.93\%$  for the thick viscosity fluid when the head was not rotated. The bolus ratio increased significantly by  $58.93\% \pm 16.22\%$  for the thin viscosity fluid and by  $72.42\% \pm 8.79\%$  for the thick viscosity fluid when the head was rotated. No significant difference was observed with or without head rotation.

The PVCR was  $94.76\% \pm 4.93\%$  for the thin viscosity fluid and  $93.83\% \pm 4.62\%$  for the thick viscosity fluid when the head was not rotated. When the neck was rotated, the PCVR was  $94.95\% \pm 3.79\%$  for the thin viscosity fluid and  $91.59\% \pm 6.91\%$  for the thick viscosity fluid. No significant difference was observed between the presence or absence of neck rotation and viscosities in terms of PCVR.

PVBS was  $114.15\% \pm 35.82\%$  for the thick viscosity fluid and was  $134.58\% \pm 57.10\%$  for the thin viscosity fluid when the head was

not rotated. PVBS was  $137.60\% \pm 61.55\%$  for the thin viscosity fluid when the head was rotated. Head rotation significantly increased pharyngeal volume.

## 4 | DISCUSSION

Evaluation of deglutition using CT has been performed since the 1990s.<sup>13</sup> Technical limitations made it difficult to evaluate dynamic 3D-CT images in the past; however, in 2011, swallowing CT was introduced as a deglutition test using a 320-ADCT, allowing the three-dimensional observation of deglutition dynamics.<sup>7</sup> This three-dimensional dynamic display enables (1) the observation of the dynamics of various organs from any direction; (2) simultaneous observation of various events; and (3) accurate quantification of dynamics. This new technology has been instrumental in new findings regarding the mechanism of swallowing movement. The timing of the swallowing dynamics is as follows: the anterosuperior movement of the hyoid bone begins, followed by the opening of the UES, closure of the laryngeal vestibule and vocal cords, and lastly, the inversion of the epiglottis.<sup>14</sup> The onset of UES opening was early as the bolus volume increased.<sup>15</sup> For example, the Mendelsohn maneuver was examined using swallowing CT, and it was reported that the end time of epiglottis inversion and the duration of epiglottis inversion were significantly prolonged by reinforcing the laryngeal elevation.<sup>16</sup> More detailed analysis of swallowing dynamics by swallowing CT will lead to further insights, which will aid dysphagia diagnosis and treatment.

Analysis of the deglutition dynamics in head rotation has been mainly performed using VFSS and high-resolution manometry (HRM). Morphological changes in the pharynx occur, and the flow path of the bolus changes and passes through the pyriform sinus on the nonrotated side.<sup>11</sup> Head rotation is effective for dysphagia patients with unilateral vocal cord paralysis or pharyngeal paralysis.<sup>17–19</sup> Regarding the dynamic changes at the entrance of the esophagus due to head rotation, the opening width of UES increases during swallowing,<sup>11</sup> and the resting pressure of UES on the non-rotating side decreases.<sup>20–22</sup> The changes in the relationship between the position of the thyroid cartilage, cricoid cartilage, and pharyngeal cavity due to head rotation affect the mechanism behind the decrease in resting pressure at UES.<sup>23</sup> Thus, head rotation is effective in patients with dysphagia and poor UES opening. Studies have evaluated the area and volume of the pyriform depression on the rotation side and the non-rotation side during head rotation without swallowing.<sup>24–26</sup> However, there have been no reports on swallowing dynamics of soft tissue or pharyngeal volume during head rotation. Therefore, in this study, we used swallowing CT to evaluate the timing of the swallowing-related organs and pharyngeal volume in patients with dysphagia diagnosed as globus pharyngeus and investigated the motor mechanism of head rotation.

Herein, head rotation significantly accelerated the onset of the time of epiglottis inversion and UES opening. There are three possible reasons for this: (1) the swallowing center; (2) the pharyngeal volume; and (3) the pharyngeal contraction force. Focusing on the swallowing center, pharyngeal swallowing is a series of movements of the

swallowing muscles programmed by the central pattern generator (CPG) in the medulla oblongata. It starts from the closure of the nasopharynx due to the elevation of the soft palate, followed by the closure of the laryngeal vestibule and glottis because of the elevation of the larynx, posterior movement of the base of the tongue, and finally, the peristaltic contraction of the pharynx and relaxation of the entrance to the esophagus followed immediately by a strong contraction of the cricopharyngeal muscle.<sup>27,28</sup> Sensory input from the pharynx and larynx via sensory receptors on the glossopharyngeal and superior laryngeal nerves is essential for triggering pharyngeal swallowing.<sup>29</sup> Therefore, we hypothesized that the swallowed material reached the pharyngeal mucosa earlier, induced perceptual input, and accelerated the time of onset of epiglottis inversion.

Focusing on the second possible reason, the pharyngeal volume before swallowing significantly increased during head rotation. This result has not been stated in past reports, and to our knowledge, ours is the first study to report this finding. We hypothesized that head rotation widened the space through which the swallowed material passed, facilitating the easy passage of the swallowed material and reaching the pharyngeal mucosa more quickly.

As for the third possible reason regarding the pharyngeal contraction force, the suprahyoid muscle on the nonrotating side is normally extended during head rotation. When a muscle is extended, its tension increases when passive tension is added to active tension,<sup>30</sup> which may result in stronger pharyngeal contractions. Conversely, concerning the time of onset of the UES opening, in addition to early sensory input resulting from the early arrival of the swallowed material to the pharyngeal mucosa, the static pressure at the esophageal entrance decreased,<sup>20</sup> facilitating the opening of UES.

There were no significant differences between the viscosities or head rotation in terms of PVCR. To date, no significant difference has been noted in PVCR owing to the difference in viscosity when the head is not rotated.<sup>31</sup> This is the first study to confirm that there was no significant difference in PVCR even when the head was rotated. In VFSS, the pharyngeal contraction area ratio correlates with swallowing pressure,<sup>32</sup> whereas in the swallowing CT, there is a correlation between the volume of the pharyngeal residue and the area on the coronal and sagittal sections.<sup>33</sup> Therefore, the PVCR may be correlated with swallowing pressure.

Swallowing CT performed in this study had an effective dose of 0.7 mSv, which is around 30% lower than the effective dose for conventional swallowing CT (1.08 mSv) and VFSS (1.05 mSv) for 5 min.<sup>7</sup> Moreover, the total effective dose was 2.8 mSv; however, since the exposure dose of ordinary simple CT is 2.8 mSv for the neck, 7.5–12.9 mSv for the chest, and 12.4–16.1 mSv for the abdomen,<sup>34</sup> swallowing CT could achieve low radiation exposure. In the future, we plan to investigate the relationship between the changes in pharyngeal volume and pharyngeal contraction force, including the suprahyoid muscles, by combining HRM with swallowing CT. We aim to directly calculate the pharyngeal contraction force only by swallowing CT. Further, we would like to perform an analysis and verification by performing a swallowing CT with head rotation in a patient with recurrent laryngeal nerve palsy.

A limitation of this study is that we could not use HRM to examine the deglutition pressure of the pharynx and the static pressure at UES. Moreover, due to the small number of cases included in the study, further validation with a larger number of participants is required. Limitations of swallowing CT include the following: synchronization of the start of swallowing and scanning is difficult in patients with impaired cognitive function. The time taken for this study is not long enough to examine the consumption of solid food which involves chewing and swallowing.

## 5 | CONCLUSION

Few studies have been conducted to quantitatively evaluate motor movement of head rotation and pharyngeal volume in patients with dysphagia diagnosed as globus pharyngeus. In this quantitative study, we noted the following: (1) head rotation accelerates the onset time of epiglottis inversion and UES opening; (2) head rotation increases pharyngeal volume; and (3) there is no interaction between head rotation and viscosity. The effectiveness of head rotation might be due to accelerating the onset time and increasing volume. The effectiveness of head rotation might be due to accelerating the onset time and increasing volume. Swallowing CT is expected to become more widely used in the future along with VFSS and VE as it allows four-dimensional analysis of the mechanism of deglutition dynamics with low radiation exposure.

## ACKNOWLEDGMENTS

The authors thank the staff of the Department of Otolaryngology, Head and Neck Surgery, and Radiology of our university for their support. The authors would also like to thank the study participants for their time and dedication.

## FUNDING INFORMATION

This work was supported by JSPS KAKENHI (grant number: 22K17608).

## CONFLICT OF INTEREST STATEMENT

The authors declare no conflict of interest.

## ORCID

Hirofumi Sei  <https://orcid.org/0000-0002-1329-9115>

Hiroyuki Yamada  <https://orcid.org/0000-0002-3458-3190>

## REFERENCES

- Ministry of Health. Labour and welfare. Outline of health, labour and welfare. *Stat.* 2020 Accessed September 10, 2022. <https://www.mhlw.go.jp/toukei/saikin/hw/jinkou/geppo/nengai18/xls/h30zu-190626.xls>
- Boyce JM, Potter-Bynoe G, Dziobek L, Solomon SL. Nosocomial pneumonia in medicare patients: hospital costs and reimbursement patterns under the prospective payment system. *Arch Intern Med.* 1991;151(6):1109-1114.
- Attrill S, White S, Murray J, Hammond S, Doeltgen S. Impact of oropharyngeal dysphagia on healthcare cost and length of stay in hospital: a systematic review. *BMC Health Serv Res.* 2018;18(1):594.
- Karaho T, Nakajima J, Satoh T, Kawahara K, Nakayama T, Kohno N. Mano-videoendoscopic assessment in the evaluation of the pharyngeal contraction and upper esophageal sphincter function in dysphagic patients. *Auris Nasus Larynx.* 2017;44(1):79-85.
- Ye-Lin Y, Prats-Boluda G, Galiano-Botella M, Roldan-Vasco S, Orozco-Duque A, Garcia-Casado J. Directed functional coordination analysis of swallowing muscles in healthy and dysphagic subjects by surface electromyography. *Sensors (Basel).* 2022;22(12):4513.
- Omari TI, Ciucci M, Gozdzikowska K, et al. High-resolution pharyngeal manometry and impedance: protocols and metrics-recommendations of a high-resolution pharyngeal manometry international working group. *Dysphagia.* 2020;35(2):281-295.
- Inamoto Y, González-Fernández M, Saitoh E. 3D-CT evaluation of swallowing: metrics of the swallowing response using swallowing CT. *Dysphagia.* 2022;37(2):237-249.
- The Oto-Rhino-Laryngological Society of Japan. Clinical practice guidelines for the diagnosis and management of dysphagia 2018. Accessed September 10, 2022. [http://www.jibika.or.jp/members/guidelines/enge\\_shougai\\_2018.pdf](http://www.jibika.or.jp/members/guidelines/enge_shougai_2018.pdf)
- Shaker R, Easterling C, Kern M, et al. Rehabilitation of swallowing by exercise in tube-fed patients with pharyngeal dysphagia secondary to abnormal UES opening. *Gastroenterology.* 2002;122(5):1314-1321.
- Wheeler-Hegland K, Frymark T, Schooling T, et al. Evidence-based systematic review: oropharyngeal dysphagia behavioral treatments. Part V—applications for clinicians and researchers. *J Rehabil Res Dev.* 2009;46(2):215-222.
- Logemann JA, Kahrilas PJ, Kobara M, Vakili NB. The benefit of head rotation on pharyngoesophageal dysphagia. *Arch Phys Med Rehabil.* 1989;70(10):767-771.
- Kanda Y. Investigation of the freely available easy-to-use software 'EZR' for medical statistics. *Bone Marrow Transplant.* 2013;48(3):452-458.
- Ergun GA, Kahrilas PJ, Lin S, Logemann JA, Harig JM. Shape, volume, and content of the deglutitive pharyngeal chamber imaged by ultrafast computerized tomography. *Gastroenterology.* 1993;105(5):1396-1403.
- Inamoto Y, Fujii N, Saitoh E, et al. Evaluation of swallowing using 320-detector-row multislice CT. Part II: kinematic analysis of laryngeal closure during normal swallowing. *Dysphagia.* 2011;26(3):209-217.
- Shibata S, Inamoto Y, Saitoh E, et al. The effect of bolus volume on laryngeal closure and UES opening in swallowing: kinematic analysis using 320-row area detector CT study. *J Oral Rehabil.* 2017;44(12):974-981.
- Inamoto Y, Saitoh E, Ito Y, et al. The Mendelsohn maneuver and its effects on swallowing: kinematic analysis in three dimensions using dynamic area detector CT. *Dysphagia.* 2018;33(4):419-430.
- Logemann JA, Kahrilas PJ. Relearning to swallow after stroke application of maneuvers and indirect biofeedback: a case study. *Neurology.* 1990;40(7):1136-1138.
- Logemann JA. The dysphagia diagnostic procedure as a treatment efficacy trial. *Clin Commun Disord.* 1993;3(4):1-10.
- Logemann JA, Rademaker AW, Pauloski BR, Kahrilas PJ. Effect of postural change on aspiration in head and neck surgical patients. *Otolaryngol Head Neck Surg.* 1994;110(2):220-227.
- Ohmae Y, Ogura M, Kitahara S, Karaho T, Inoue T. Effects of head rotation on pharyngeal function during normal swallow. *Ann Oto Rhinol Larynx.* 1998;107(4):344-348.
- McCulloch TM, Hoffman MR, Ciucci MR. High-resolution manometry of pharyngeal swallow pressure events associated with head turn and chin tuck. *Ann Otol Rhinol Laryngol.* 2010;119(6):369-376.

22. Takasaki K, Umeki H, Kumagami H, Takahashi H. Influence of head rotation on upper esophageal sphincter pressure evaluated by high-resolution manometry system. *Otolaryngol Head Neck Surg.* 2020; 142(2):214-217.
23. Welch RW, Luckmann K, Ricks PM, Drake ST, Gates GA. Manometry of normal upper esophageal sphincter and its alterations in laryngectomy. *J Clin Invest.* 1979;63(5):1036-1041.
24. Tsukamoto Y. CT study of closure of the hemipharynx with head rotation in a case of lateral medullary syndrome. *Dysphagia.* 2000;15(1):17-18.
25. Yamashina A, Tanimoto K, Ohtsuka M, et al. A morphological comparison of the piriform sinuses in head-on and head-rotated views of seated participants using cone-beam computed tomography. *Oral Radiol.* 2008;24:64-70.
26. Nakayama E, Kagaya H, Saitoh E, et al. Changes in pyriform sinus morphology in the head rotated position as assessed by 320-row area detector CT. *Dysphagia.* 2013;28(2):199-204.
27. Miller AJ. Significance of sensory inflow to the swallowing reflex. *Brain Res.* 1972;43(1):147-159.
28. Jean A, Car A. Inputs to the swallowing medullary neurons from the peripheral afferent fibers and the swallowing cortical area. *Brain Res.* 1979;178(2-3):567-572.
29. Ootani S, Umezaki T, Shin T, Murata Y. Convergence of afferents from the SLN and GPN in cat medullary swallowing neurons. *Brain Res Bull.* 1995;37(4):397-404.
30. Neumann DA. *Kinesiology of the Musculoskeletal System: Foundations for Rehabilitation.* 3rd ed. Mosby; 2016.
31. Ito Y, Inamoto Y, Saitoh E, et al. The effect of bolus consistency on pharyngeal volume during swallowing: kinematic analysis in three dimensions using dynamic area detector CT. *J Oral Rehabil.* 2020; 47(10):1287-1296.
32. Leonard R, Rees CJ, Belafsky P, Allen J. Fluoroscopic surrogate for pharyngeal strength: the pharyngeal constriction ratio (PCR). *Dysphagia.* 2011;26(1):13-17.
33. Mulheren RW, Inamoto Y, Odonkor CA, et al. The association of 3-D volume and 2-D area of post-swallow pharyngeal residue on CT imaging. *Dysphagia.* 2019;34(5):665-672.
34. Cohnen M, Poll L, Puettmann C, Ewen K, Saleh A, Modder U. Effective doses in standard protocols for multi-slice CT scanning. *Eur Radiol.* 2003;13(5):1148-1153.

**How to cite this article:** Kochi K, Sei H, Tanabe Y, et al. The dynamics of deglutition during head rotation using dynamic 320-row area detector computed tomography. *Laryngoscope Investigative Otolaryngology.* 2023;8(3):746-753. doi:[10.1002/liv2.1082](https://doi.org/10.1002/liv2.1082)